

- 20% of > 70 y i.e. common

Varicose eczema

Disclaimer:
Read the disclaimer at medimaps.co.uk/disclaimer

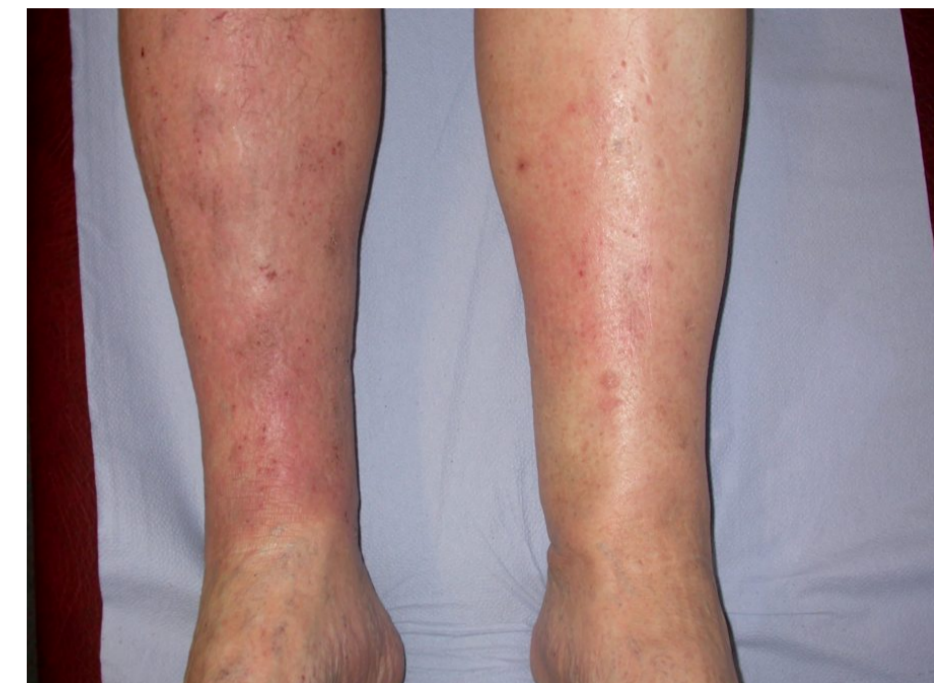
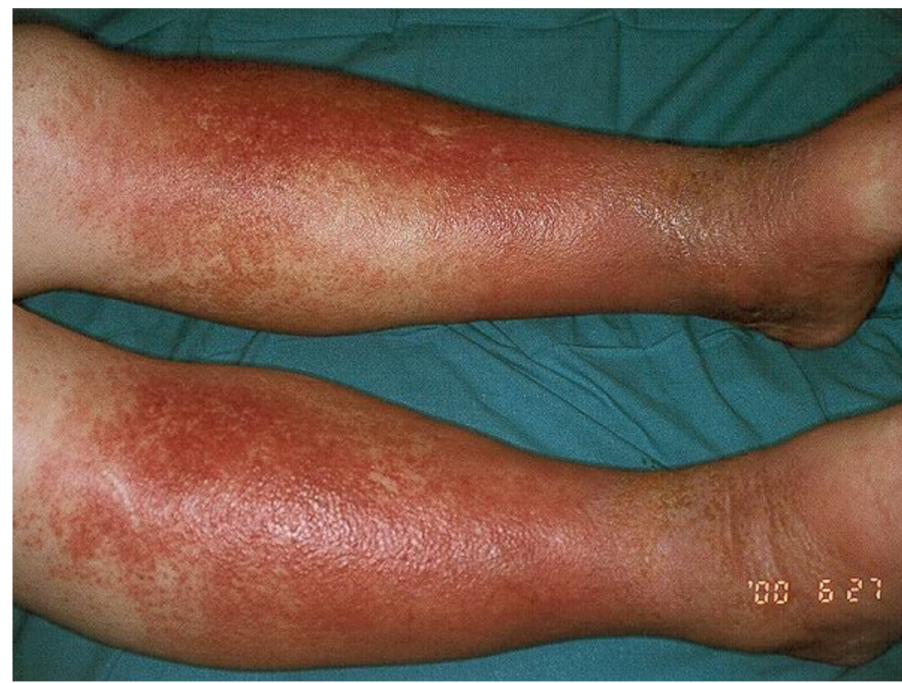References:
1. cks.nice.org.uk
2. pcds.org.uk
3. Walsall Alliance Federation, Walsall, dermatology consultant, July 2017

Images from Primary Care Dermatology Society
pcds.org.uk

Symptoms

- Lower limb diffuse erythema
- Often bilateral
- Dry, scaly or weeping
- Brown discolouration
- Varicose veins may or may not be visible

- Often misdiagnosed as bilateral cellulitis.
- Bilateral cellulitis is rare (dermatology consultant has seen in once in 10 yr of practice).



Investigations

- Nil tests.
- Clinical diagnosis.
- Swabs if suspecting infection.

Management

Emollients

- Use regularly

Steroids

- Dermovate OD for 10/7
- THEN
- alternate days for 10/7
- THEN
- twice weekly for 2/52
- THEN
- PRN

if using regularly and risk of atrophy use

Protopic 0.1% ointment BD initially, then OD once settled.

Potassium permanganate soaks

- If weeping/oozing

Antibiotics

- Swab and await result
- OR
- Treat empirically for 10-14/7

Flucloxacillin AND Penicillin V

Medicated banadages

if severe or resistant patches

- Potent or very potent steroid under ZIPZOC or Viscopaste banadage.
- Replace bandage once or twice a week.
- Can take up to 6-8/52 to settle.
- Be aware contact dermatitis can develop. Often develop eczema in distant sites. Consider patch testing.

Compression stockings

- Check ABPI.
- Then give grade 2 compression stocking.