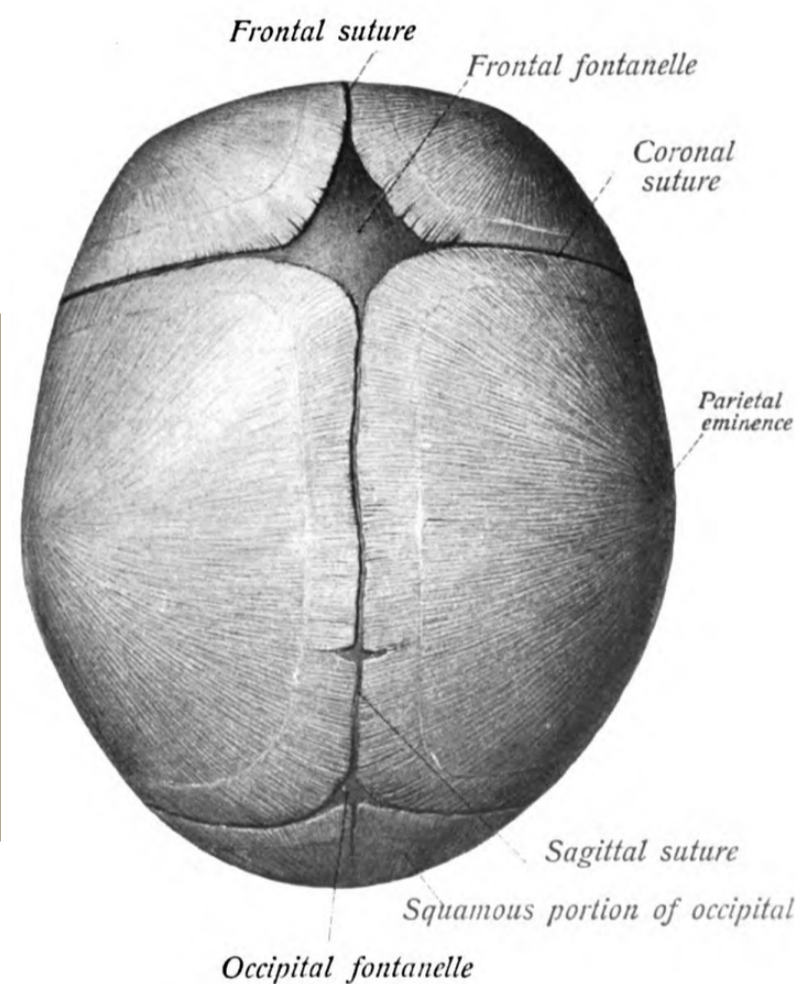
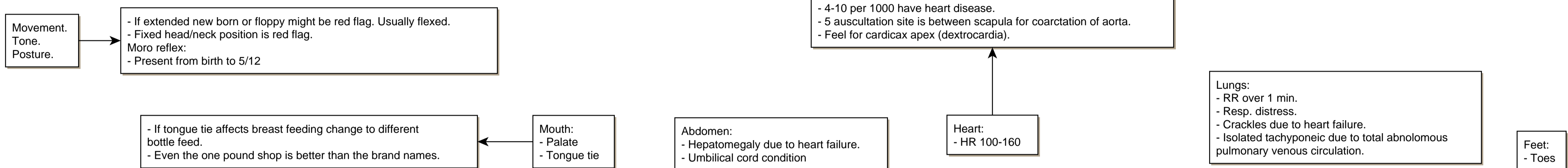


Newborn baby check

- Should occur no more than 10/52.

Disclaimer:
Read the disclaimer at medimaps.co.uk/disclaimer

References:
1. Forteen Fish whiteboard 6 week check
2. GP Notebook
3. Norfolk and Norwich University Hospital Newborn examination guidelines
4. http://www.flaticon.com/free-icon/baby-wearing-a-diaper_20734#term=baby&page=4&position=38
5. https://en.wikipedia.org/wiki/Sagittal_suture
6. Paediatric consultant, RCGP, Nov 2016.
7. Childhood healthcare conference, New Cross Hospital
8. Paediatric consultant MediConf webinar, June 2023



Fontanelle:
- Anterior (10-50mm) and posterior (5mm).
- Should close by 2 yrs.

- If elongated head, you should be concerned about early fusion of the sagittal suture.
- Needs urgent referral to the max/fax/paediatrician as it can cause raised ICP.
- Can check for fusion by holding one bone and seeing if the other bone on the other side of the fontanelle moves.
- If plagiocephaly and parents not happy = tell them to buy Gt Ormond St helmet.

Causes of delayed closure:

- Hydrocephalus.
- Trisomies e.g. Down's syndrome.
- Congenital hypothyroidism.
- Skeletal dysplasias, such as achondroplasia or Russell-Silver dwarfism.
- Metabolic causes e.g. mucopolysaccharidoses.

Face:
- Asymmetry

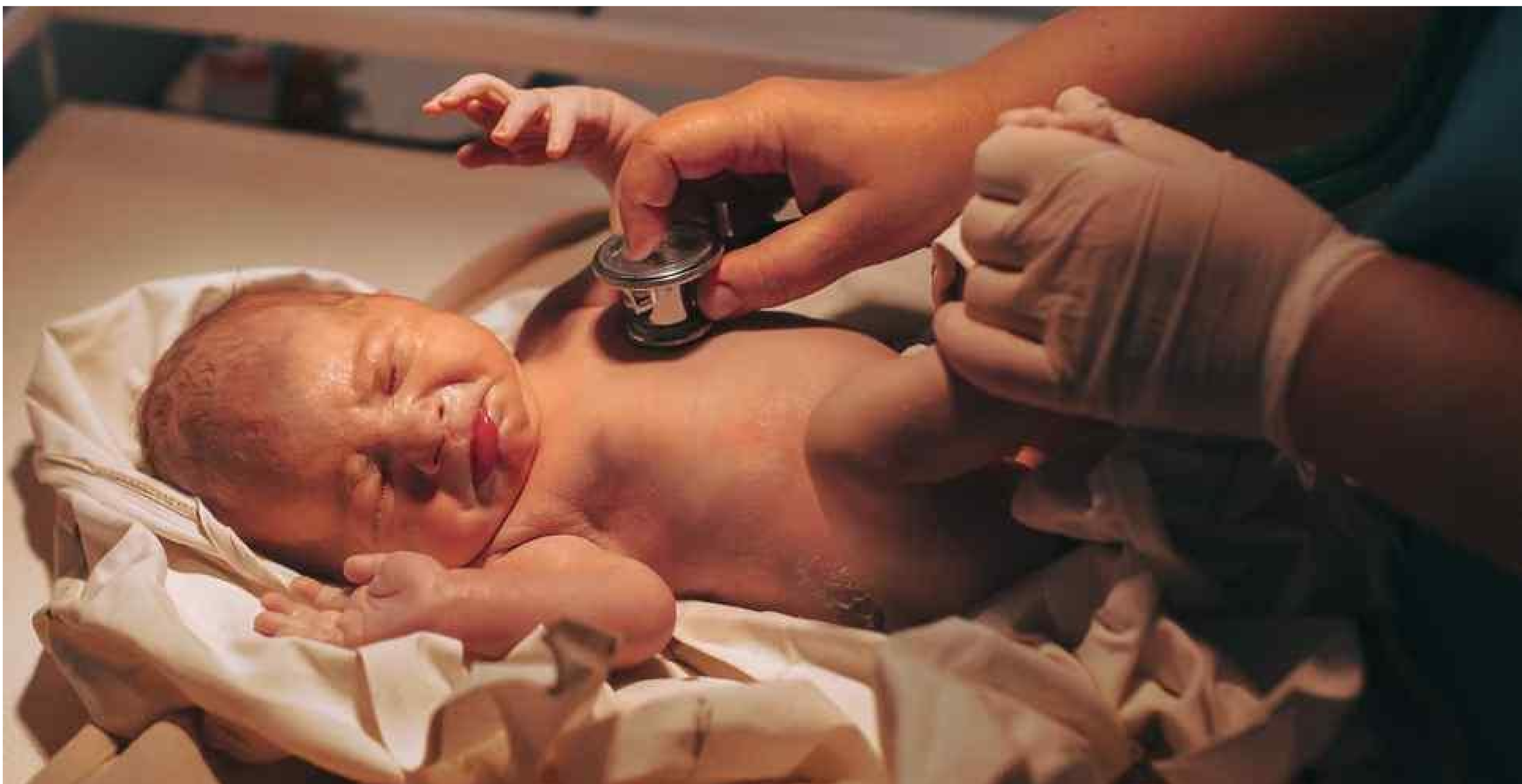Eyes:

- Fix and follow response.
- Light reflex symmetrical or not.
- Congenital cataracts.
- Red reflex. 7/7 doubling time for retinoblastoma. Try dark room.
- Make sure vessels are going to disc i.e. normal.
- If random vessels then ?retinoblastoma. Black pt have pale disc.
- If no red reflex refer to consultant ophthalmology by 11/52.
- If difficult to see, put on moms shoulder, turn light off, use biggest circle of light, turn brightness down..

Eyes:
- Red reflex.
- Squints.

Ears:
- Pre auricular tags.

Ears:
- Pre auricular tags.



Skin:

Oedema:
- Weight gain due to fluid retention from heart failure.
- Weight loss of 10% is normal. Then regain birth weight by 2/52.

Acrocyanosis:
- Bluish hands and feet. Nil treatment needed.

Cafe au lait:
- If >3cm or > 6 spots, consider cutaneous neurofibromatosis.
- May appear after 6/52.

Central cyanosis:
- Refer to paed.

Erythema toxicum neonatorum:
- Up to 2/52 post delivery. Nil treatment needed.

Jaundice:
- Purplish colour. Hb abnormality. Refer to paed.

Plethora:
- Purplish colour. Hb abnormality. Refer to paed.

Port wine stain:
- Capillary malformation. Needs paed referral if over forehead (Sturge-Weber syndrome) or around eye (glaucoma). Laser treatment.
- If big are followed up. Small do not need referral.

Salmon patch (stork mark):
- Occur in 50% of babies. Forehead, eyes, neck. Dissapear by 4y, sometimes longer.

Strawberry naevus (haemangioma):
- Benign tumour of blood vessels. Self resolves. Usually dissapears by 7y.
- If lots, can start to consume platelets so refer to paediatrics.
- Refer if large as can cause cardiac compromise, or if over eye.

??? jaundice management ???

Hands:
- Fingers

Spine:
- Dimple is common.

Femoral pulse

Hip:
- Barlow (press down on bent knees)
- Ortolani

Genital:
- Patency
- Testicular descent

Spine:
- Dimple is common.

Femoral pulse

Hip:
- Barlow (press down on bent knees)
- Ortolani

- Height of knees when flexed.
- Asymmetric skin creases.
- Limitation of abduction.
- To be seen by 10/52 by orthopaedics.

Genital:
- Patency
- Testicular descent

- See 'Paediatric urology' algorithm for undescended testes.

