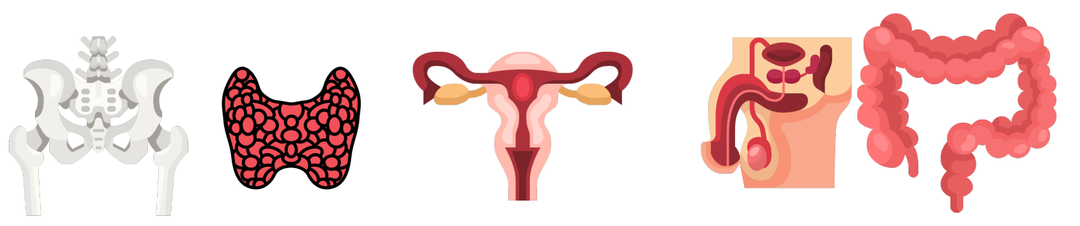

POCUS

MediMaps

MEDIMAPS.CO.UK | 21ST OCT 2023

DRAFT!

Ultrasound scanning (POCUS for a GP)

- You do not have RTA victims in resus.
- So chill out and relax.
- You are not a radiologist or a sonographer.
- Only use USS if:
i) It is a YES/NO question.
ii) It will take < 5min.

Disclaimer:
Read the disclaimer at medimaps.co.uk/disclaimer

References:
1. Ultrasound for the generalist. Sarb Clare, Chris Duncan. 2021.
2. www.pocus101.com
3. www.ddxof.com
4. Pragmatic POCUS for Urgent and Primary Care: Diagnosing Renal, Gallbladder and Aortic Pathology, Clarius, Youtube.
5. Clarius.com, Youtube channel.
6. Sonosite, Youtube channel.
7. AnatomyZone, Youtube channel.
8. Ultrasonography of Superficial Soft-Tissue Masses: Society of Radiologists in Ultrasound Consensus Conference Statement April 2022.

CONTINUOUS WAVE DOPPLER
- USS waves constantly emitted.
- USS waves continuously analysed.
- Measures very high speed flows i.e. heart.

COLOUR DOPPLER
- Measures mean frequency shift (speed slow).
- Detects flow direction i.e. BART.
- Changes with insonation angle, hence, at 90o no flow detected (can use box steering to compensate).

POWER DOPPLER
- Measures total amplitude of the doppler frequency (density of RBC).
- Does NOT detect flow direction, hence, one colour.
- Independent of insonation angle.
- Very sensitive for slow flow vessels e.g. MSK.

JOINTS

SHOULDER

BICEPS TENDON

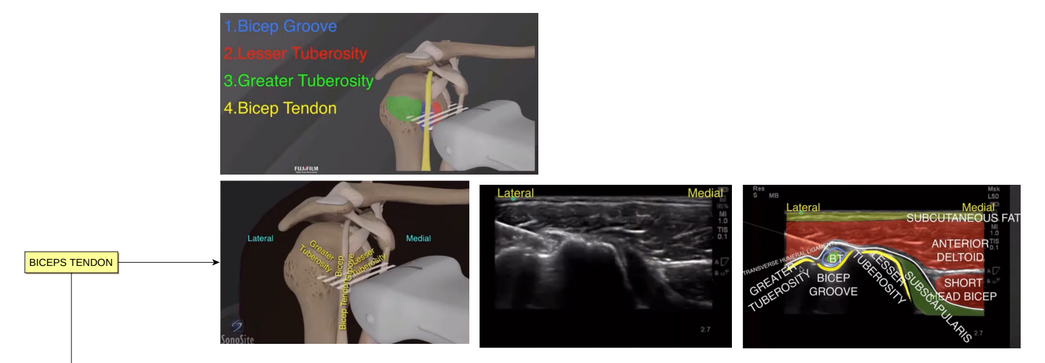

SUBACROMIAL BURSA

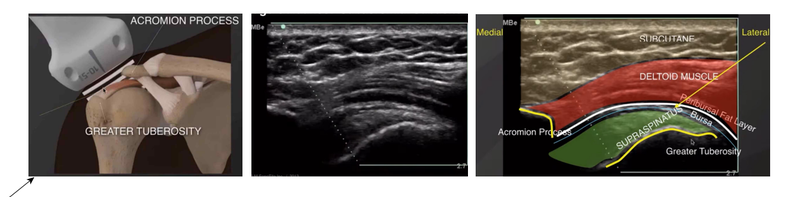

- Position pt = Pt places hand on hip and pushes elbow back to open up the access to the bursa.
- Probe = Linear.
- Location = Enter anteriolaterally.
- Get under double hyperechoic line (of the peridertoid fat).

https://www.youtube.com/watch?v=_rQx6mXq698

https://www.youtube.com/watch?v=MJiW0sWMsmA

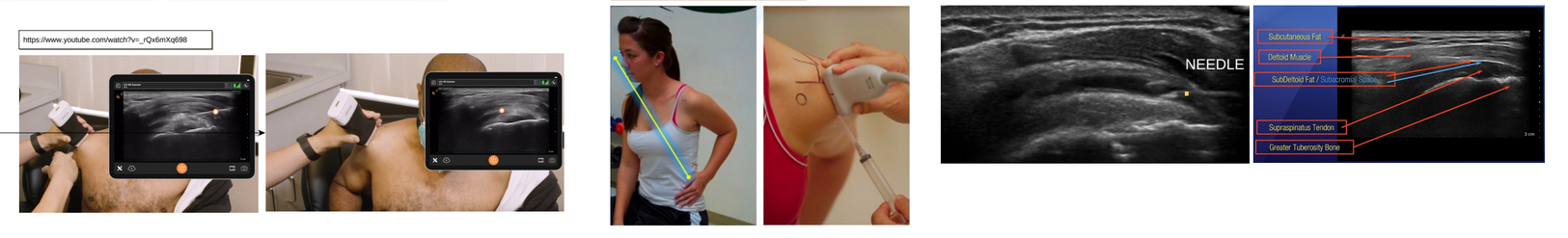

ACROMIOCLAVICULAR JOINT

- Position pt = Sitting.
- Probe = Linear.
- Location = In-plane in long axis of joint (transverse view).

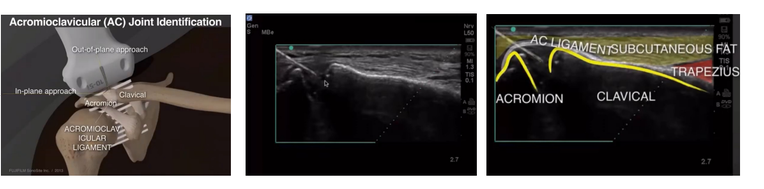

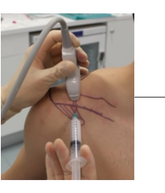

- Position = Sitting.
- Probe = Linear.
- Position = In-plane in short axis of joint (longitudinal view).
- Remember the joint is diagonal, not straight up and down. The clavicle will be above and coming down at an angle to the acromium. So angle the probe.

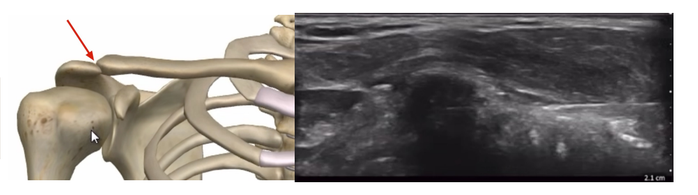

GLENOHUMERAL JOINT

- Position Pt = Sitting with affected arm crossed across to other shoulder or holding other elbow, hence, opening up the GH joint.
- Probe = Linear.
- Location = Enter posteriorly, parallel and inferior to the scapula spine, under acromion. In-plane.

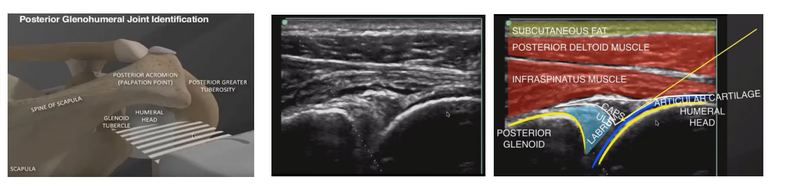

- Position = Sitting with affected arm tucked into side.
- Probe = linear.
- Location = Enter posteriorly, parallel and inferior to the scapula spine, under acromion. Out-of-plane, as makes it less likely you will scrape against the humeral cartilage. Enter 1-2 cm below probe and angle up slightly.

https://youtu.be/tly-8awLbS0?feature=shared&t=1342

https://www.youtube.com/watch?v=uYYwpOtknRI

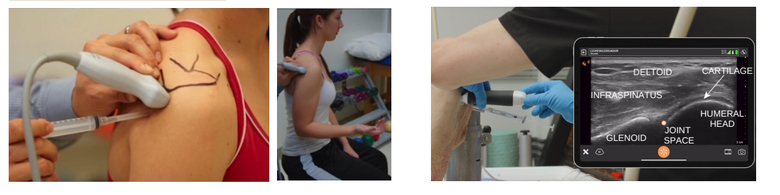

KNEE

- Position = Lying flat, with knee at 30o flexion.
- Probe = linear.
- Location = Enter laterally, parallel and inferior to the scapula spine, under acromion. In-plane.

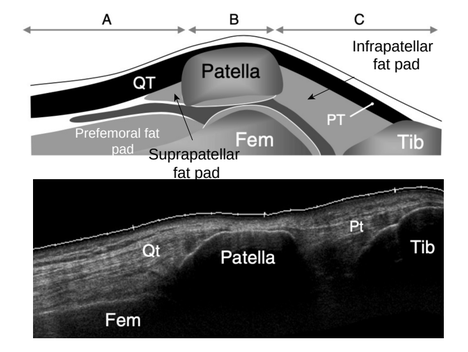

https://www.youtube.com/watch?v=fWLgKRjf69c

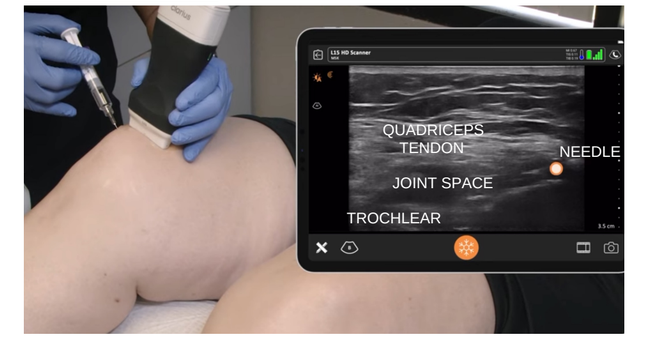

https://www.youtube.com/watch?v=[illegible]

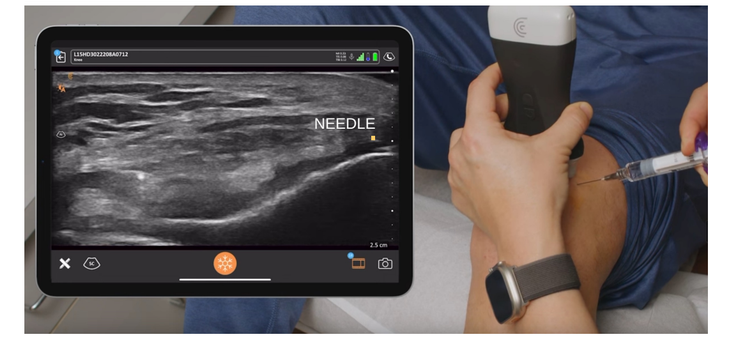

https://www.youtube.com/watch?v=CxLLuANuPXg

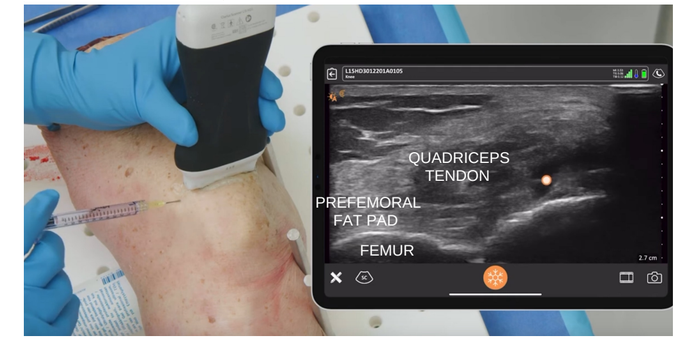

https://www.youtube.com/watch?v=[illegible]

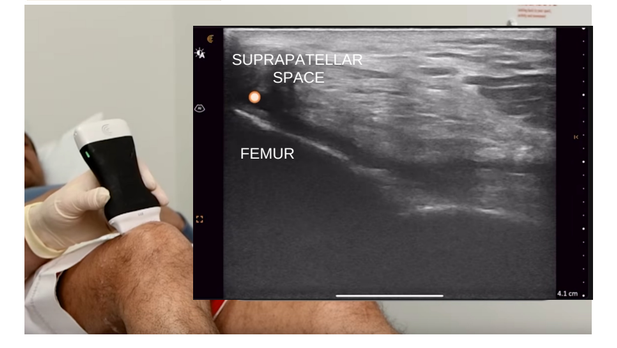

HAND (CARPAL TUNNEL SYNDROME)

- Position = Sitting or lying flat with hand palmar side up.
- Probe = linear.
- Location = Enter ulnar side, ensuring you have marked and avoided ulnar artery.

https://www.youtube.com/watch?v=[illegible]

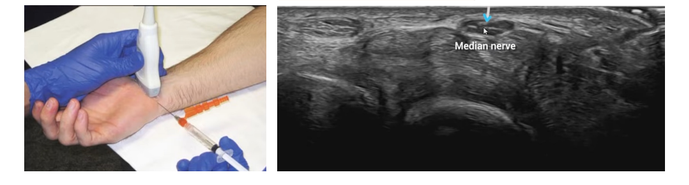

https://www.youtube.com/watch?v=[illegible]

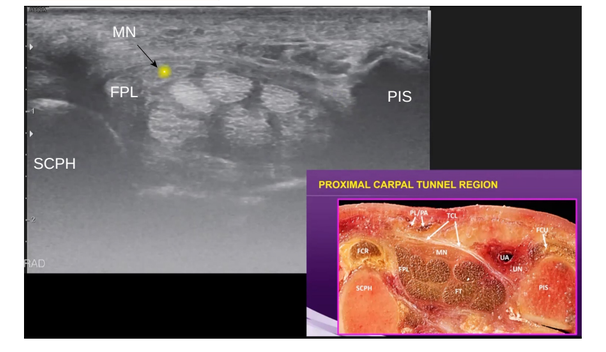

PLANTAR FASCIITIS

https://www.youtube.com/watch?v=[illegible]

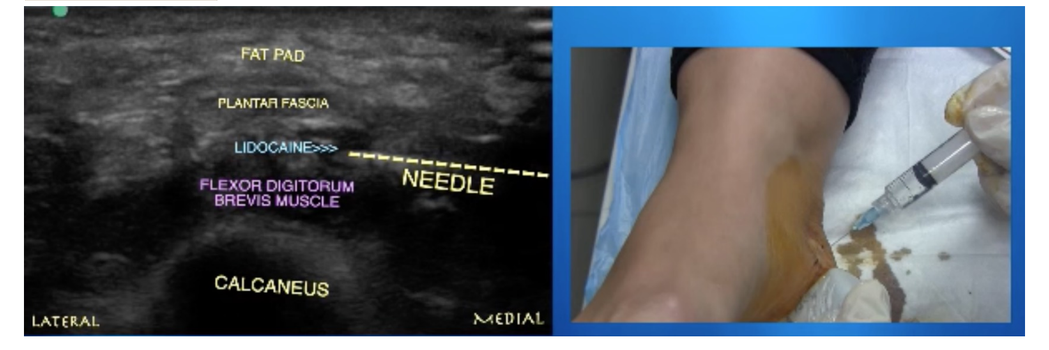

https://www.youtube.com/watch?v=[illegible]

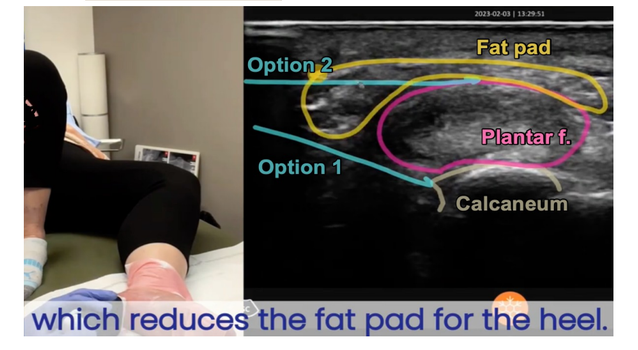

ORGANS

Images from:
Ultrasound for the generalist. Sarb Clare, Chris Duncan. 2021

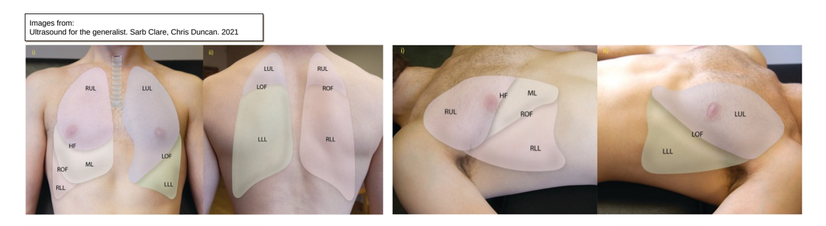

Images from:
Ultrasound for the generalist. Sarb Clare, Chris Duncan. 2021

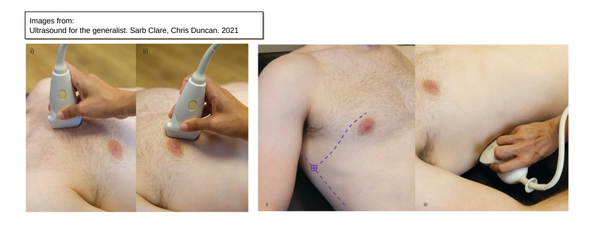

Images from:
www.pocus101.com

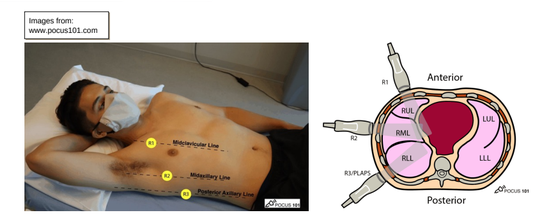

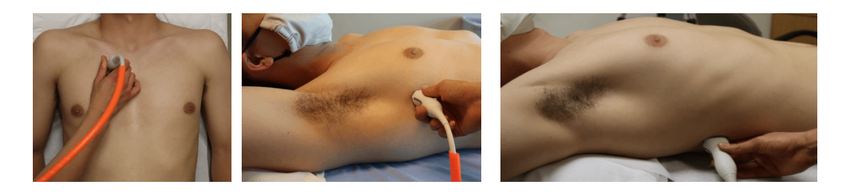

LUNGS

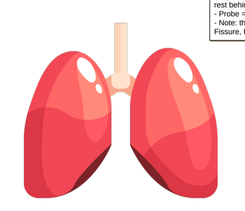

- BLUE protocol (six point) is sufficient.
- You don't have time for lawnmowing.
- However, consider lawnmowing the front and back if you really suspect there is Covid or some other viral pneumonia.
- BLUE was developed in 2008 for acute SOB.
- Has 90% diagnostic accuracy.
- Position = Sitting in chair, resting against couch or lying flat on couch. Ask them to raise arm up and rest behind head.
- Probe = All 6 positions longitudinal.
- Note: the lung anatomy (see right). Horizontal Fissure, Right Oblique Fissure.

- Remember in the normal lung we are NOT looking at lung tissue substance (parenchyma).
- It's just full of air, and we will not see the tiny alveoli tissue.
- All we see is the pleura and the grey stuff is simply artefact.
- As opposed to liver and spleen and kidney's etc which is actual real tissue that you are visualising.

- Massive difference in six positions depending on source !

1) Midclavicular line, 2nd intercostal space.

2) Pocus101 = Midaxillary line, 6-7th intercostal space, lateral to the nipple line, which makes more sense is it will actually assess the Rt middle lobe.
BLUE protocol = Just medial to the nipple.

3) Pocus101 = Posterior axillary line, 10-12th rib space. i.e. Posterolateral alvelolar and/or pleural syndromes (PLAPS)
BLUE protocol = posterior axillary line, and intersection nipple line.

Pulmonary effusion

- Normal to see mirror image artifact in PLAPS position.

- Is best place to look for pleural effusion.
- Signs to confirm include:
- See spine above diaphragm.
- Consolidated lung floating in effusion (Jellyfish sign).
- Can do M-Mode if you see Jellyfish, will see Sinusoid sign (sine wave).

Lung sliding
- Present
  - B lines → **Pulmonary oedema**
  - A lines → Vascular analysis
    - Thrombosed vein → **PE**
    - Free vein
      - No PLAPS → **COPD/Asthma**
      - PLAPS → **Pneumonia**
- Any
  - A/B/C lines → **Pneumonia**
- Abolished
  - B lines → **Pneumonia**
  - A lines
    - Lung point → **Pneumothorax**
    - No lung point → **More tests needed**

- Artefact from air in alveoli and thickening of the inter-lobular septa due to fluid or fibrosis.

- Causes include:
- Pulmonary oedema.
- Acute lung injury.
- Lung fibrosis.
- Interstitialpneumonia/pneumonitis.

- ≥3 considered pathological.
- Vertical lines.
- Arise from the pleural line.
- Move with lung sliding.
- Extend to bottom of screen.
- If many B lines they combine to make waterfall sign.

PE:
Bilateral A lines.
DVT in upper or lower extremities.
Right Ventricular enlargement (if massive/submassive)

COPD/Asthma:
Bilateral A lines.
- ↓ Lung sliding.

Pneumonia:
- Note: Although consolidation makes you think pneumonia, it can also be due to atelectasis from airway obstruction (i.e. mucous plug) or extrinsic compression (i.e. large pleural effusion).

- Four stages of consolidation:
1) Subpleural consolidation, small pockets of echo-poor areas under the pleura.
2) Shred sign, consolidation bordered by normal lung.
3) Severe consolidation.
4) Hepatisation.

- Possible small pleural effusion.
- ↓ Lung sliding due to thickened pleura in severe cases.
- Dynamic air bronchograms.

Pneumothorax:
Bilateral A lines from parietal pleura reflection.
- Lung sliding absent when parietal and visceral pleura become separated by air (pneumothorax) or fluid (pleural effusion).
- If you think nil sliding, then use M-mode to confirm by looking for stratosphere/barcode sign and absence of lung pulse.
- Look for lung point (move probe laterally). Can also see downward deflection of pleural layer.

LIVER

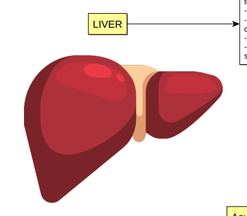

- Position = Lying flat on couch. Ask them to bend legs to soften the abdo muscles.
- Ask them to raise arm up and rest behind head.
- If ribs blocking, take and hold a deep breath. Rotate probe obliquely to align with the intercostal spaces.
- Probe in mid-axillary line at 10-11th intercostal space.
- Craniocaudal length < 16cm spanning 5-11th intercostal spaces.

Image from:
www.pocus101.com

www.sonomojo.org

- How to scan RUQ efficiently?
- The anterior, mid, and posterior axillary lines will provide you with landmarks.
- In the anterior axillary line is the gallbladder.
- In the mid axillary line you ll find the IVC.
- In the posterior axillary line is the kidney.
- Because these three structures are stacked anterior to posterior in this order, you can guide your probe movement accordingly.
- If you re looking for kidney and see gallbladder, simply sweep or fan posteriorly.
- If you re looking for gallbladder and see IVC, just sweep or fan anteriorly.

Acute hepatitis
- ↓ Echogenicity, as fluid build up.
- ↑ Brightness of portal vein walls.
- Parenchyma resembles a "starry sky" appearance, whereby the portal vein walls appear as hyperechoic "stars" on a background of dark, edematous hepatocytes.
- Usually enlarged (craniocaudal length ≥16.0cm in the midclavicular line) due to oedema.
- Acute hepatitis occurs when the liver has an inflammatory reaction to an injury, whether traumatic, infectious, drug-induced, or autoimmune. This causes the liver to become oedematous and enlarged.

Chronic hepatitis/cirrhosis:
- ↓ Brightness of portal vein walls.
- ↑ Echogenicity relative to kidney.
- Usually small/atrophic liver.
- Surface (capsular) nodularity (88% sensitivity, 95% specificity) for cirrhosis.

Fatty Liver Disease (Hepatic Steatosis):
- ↓ Brightness of portal vein walls.
- ↑ Echogenicity.
- Usually enlarged.

GALLBLADDER

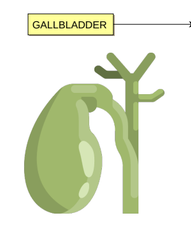

- Position = Lying flat on couch. Ask them to bend legs to soften the abdo muscles. Gallbladder may require left lateral decubitus position.
- Ideally fasting.
- Probe = curvilinear.
- Location = Can start at upper abdo in midline in sigital and move towards rt . Look for portal vein, echogenic wall due to fat from intestine. Right next to it is sacular structure = gallbladder. If unsure if you found portal vein, you can add colour doppler and it will light up, but the gallbladder next to it will not. OR can start at Rt flank and view the liver and then move across to the front of the abdo.
- The exclamation sign = the gallbladder is the long line and the portal vein is the dot.

Gallbladder wall measurement:
- Normal anterior gallbladder wall thickness = <3mm.
- Some sources use <5mm thickness to ↑ specificity.

CBD measurement:
- Normal = <5mm.
- However, with every decade of life after 50, diameter ↑ by one mm e.g. 60y old can have CBD 6mm.
- Note: If cholecystectomy, normal CBD is <10mm.
- Tip: Difficult to visualise, let alone measure the CBD. So if CBD doesn t appear wider than 50% the portal vein diameter, it is unlikely any bile duct pathology is present.

Choledocholithiasis
- Choledocholithiasis occurs when gallstones lodge in the bile ducts and bile can no longer flow, instead backing up into the liver.
- Most cases are symptomatic and require removal of the stones since ascending cholangitis (acute bacterial infection of the biliary tree) is a common complication with high morbidity/mortality.
- Calculi in gallbladder and/or CBD.
- Dilated CBD >5mm.
- Remember, with every decade of life after 50, diameter ↑ by one mm e.g. 60y old can have CBD 6mm.

Cholecystitis
- Gallbladder inflammation.
- 95% due to drainage ducts obstruction from stones.
- Other 5% due to sludge (fine bile crystals mixed with proteinaceous debris and fluids) or tumours.
- Distension (>4cm transverse and >9cm longitudinal).
- Anterior gallbladder wall thickening >3mm.
- Pericholecystic fluid.

Cholelithiasis
- Gallstones anywhere along the biliary tree.
- If in the gallbladder = hyperechoic with posterior shadowing.
- May move if pt changes position.
- Smaller stones may not be directly visible within the lumen, but may show "twinkling artifact" with color doppler.
- If polyp, it would not cast a shadow.

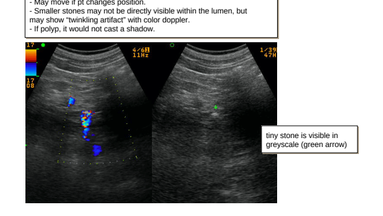

tiny stone is visible in greyscale (green arrow)

RENAL

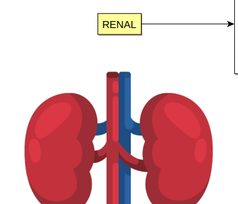

- Position = Lying flat on couch, or sitting upright, or. left/right lateral decubitus position.
- Probe = Curvilinear.
- Rt kidney = Rt mid axillary line 10-11th intercostal space. Rotate 10-20o counter clockwise to get in between ribs. For transverse rotate 90o counter clockwise (indicator will be pointing posteriorly).
- Lt kidney = Lt post axillary line 8-10th intercostal space. For transverse rotate 90o counter clockwise (indicator will be pointing anteriorly).

Hydronephrosis
- The structures closest to the obstruction will be the first to be dilated.
- So the order of hydronephrosis will be:

Grade I	Grade II	Grade III	Grade IV
Renal pelvis	Major calyces	Minor calyces	Renal cortex
MILD	MODERATE		SEVERE

- Note: Grade 1 occurs in healthy pt that have not voided for a long time.
- So ask pt to void pre scan.

Image from:
www.pocus101.com

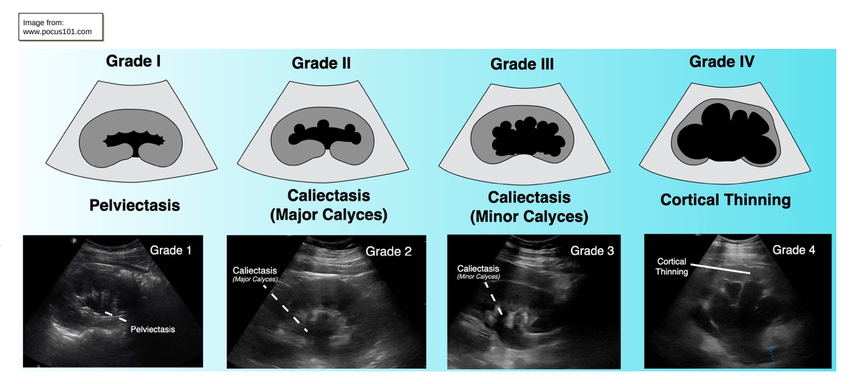

Renal cysts
- Thin-walled, round, smooth, no septations or internal components, located in cortex or by pelvis, not connected to the calyces.

Renal stone
- Located within the renal parenchyma, at the ureteropelvic junction (between ureter and renal pelvis), within the ureter, or at the ureterovesical junction (between ureter and bladder).
- Can be detected using four features:
1) Direct visualisation; Hyperechoic mass with shadowing. Rare to see.
2) Hydronephrosis; If small stone will not cause this. If mild then likely <5mm stone and good chance will pass it.
3) Absence of ureteral jets; (see bladder below).
4) Twinkling artifact; using colour doppler, multicoloured high-intensity signal located behind renal stones.

Renal mass
- Hyperechoic lesion with no accoustic shadow = must consider renal cell carcinoma.

SPLEEN

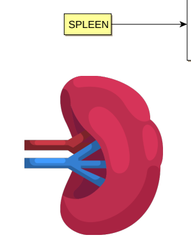

- Position = Lying flat on couch.
- Hold a deep breath to further widen the intercostal spaces.
- Align probe obliquely with the intercostal space by rotating slightly clockwise.
- Probe at 7-8th intercostal space very posterior, so knuckles to the bed.
- Craniocaudal dimension <12 (taller males ≤14cm).

BLADDER

- Position = Lying flat on couch. Ask them to bend legs to soften the abdo muscles.
- Bladder vol = Width x Depth x Height x 0.72.
- Normal post-void volume is <50 mLl, but <100 ml normal in pt > 65y.

Uretral jets (kidney stones)
- Slowly scan through in transverse and focus on the trigone (located on the posterior wall of the bladder).
- Use colour doppler (scale 10-20cm/s) or power doppler.
- Can take 5-10 mins before see bilateral jets.
- If seen, rules out complete obstruction of a specific ureter with high specificity.

Bladder stone
- Hyperechoic, mobile, acoustic shadow.

Bladder mass
- Could be Ca (TCC), bladder diverticulitis, congenital outpouching of the bladder wall or bloods clot (get bladder iirigation and rescan and pt to move onto side and mass will be different position compared to first scan).
- Echogenic, irregular shape on bladder wall
OR
- ↑ Bladder wall thickness.

HEART

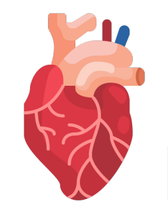

- Position = Lt lateral decubitus.
- Probe = phased array.
- ***Screen indicator = RIGHT side of screen***, purely due to convention in some countries.
- This is totally the opposite of other scans we do.
- e.g. For transverse scans it's as if you are slicing the pt in transverse, and looking up the feet towards the head, like a CT scan.
- For echo, imagine you are standing on the RIGHT of the pt, and the probe marker is on the RIGHT, and the screen marker is on the RIGHT too, and so the USS cuts you are making are also lined up this way i.e. for PLAX, the heart base is on the right of the screen (the atriums), the apex (ventricles) is on the left of the screen.

Image from:
www.heartwest.com.au

Parasternal Long Axis (PSLA or PLAX)
- Location = point indicator to pt's Rt shoulder (10 o'clock), 3rd-4th intercostal space ≈ nipple line in male, Lt parasternal border, 10-16cm deep.
- Image = cross-section from the base to the apex.
- LEFT ventricle is on the LEFT of the screen.

Image from:
www.techmed.sk

Image from:
Ultrasound for the generalist. Sarb Clare, Chris Duncan. 2021

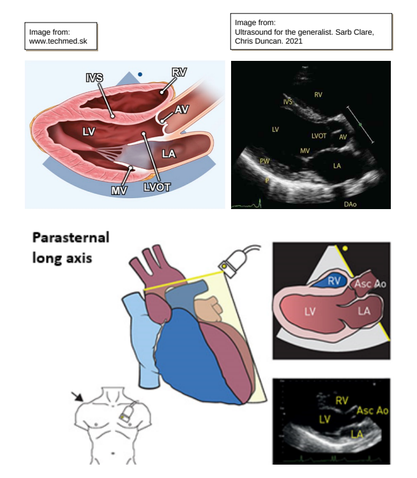

Parasternal Short Axis (PSSA or PSAX)
- Location = From PLAX rotate 90o so indicator pointing to Lt shoulder, 2 o'clock.
- Image = heart in transverse.
- There are three levels to cut of the heart.

1) Mid-papillary level.
2) Mitral valve level (Fish mouth view).
3) Aortic valve level (Mercedes Benz view).

Image from:
www.pocus101.com

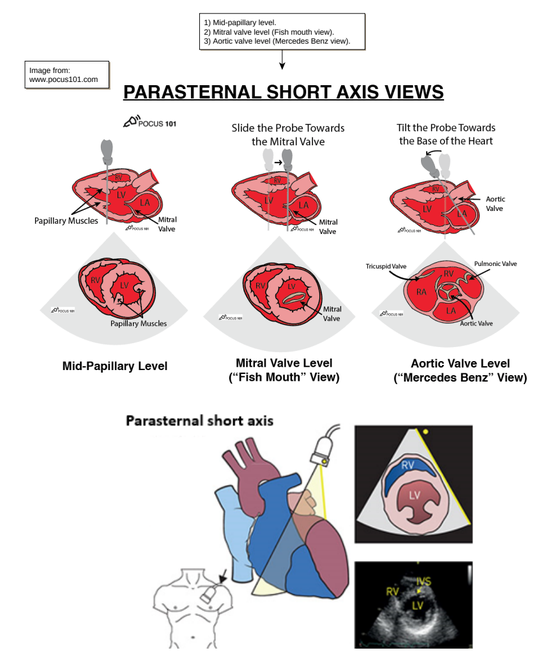
PARASTERNAL SHORT AXIS VIEWS
POCUS 101
Slide the Probe Towards the Mitral Valve
Tilt the Probe Towards the Base of the Heart
Papillary Muscles
Mitral Valve
Aortic Valve
Tricuspid Valve
Pulmonic Valve
Mid-Papillary Level
Mitral Valve Level ("Fish Mouth" View)
Aortic Valve Level ("Mercedes Benz" View)
Parasternal short axis

Apical Four-chamber
- Location = Cardiac apex with indicator to Lt shoulder, shallow angle.
- Image = Typical 'heart-shaped' four-chamber view.
- Note: the ventricles are closest to the top of the screen, and the left ventricle will be on the RIGHT of the screen given how the probe has the marker to the RIGHT.

Image from:
www.techmed.sk

Image from:
Ultrasound for the generalist. Sarb Clare, Chris Duncan. 2021

Image from:
www.pocus101.com

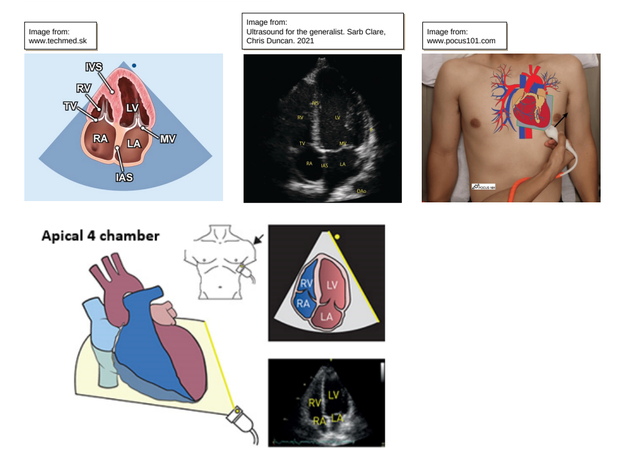

SMALL BOWEL

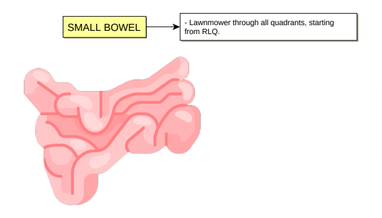

- Lawnmower through all quadrants, starting from RLQ.

Small bowel obstruction
- Two out of three of following has sensitivities and specificities of over 90% for SBO.

- Dilated bowel loops (diameter > 3cm).
- Ineffective or absent peristalsis, seen as a "whirling" of intra-luminal contents.
- Collapsed colonic lumen.

PANCREAS

???

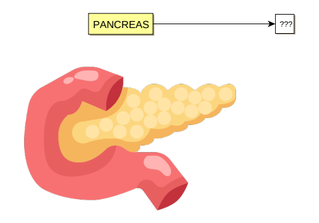

EYE

- Position = Lying nearly flat.
- Apply thick layer of gel.
- Can apply Tegaderm over eye first.
- Anchor your hand to nose or face to ↓ pressure.
- Probe = Linear. Occular preset.

Images from:
www.ddxof.com

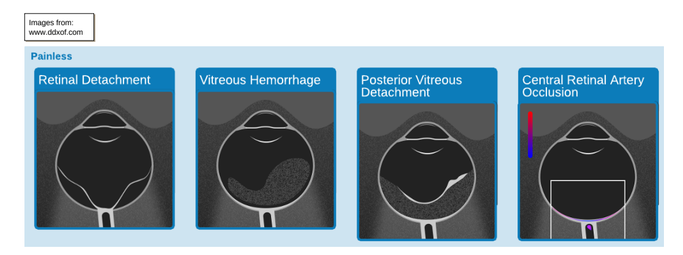
Painless
Retinal Detachment
Vitreous Hemorrhage
Posterior Vitreous Detachment
Central Retinal Artery Occlusion

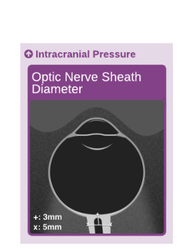



Retinal detachment
- Low gain.
- Separation of the sensory retina from the underlying retinal pigment epithelium.
- Cuts off blood supply to rods and cones, can cause permanent vision loss.
- Thick/hyperechoic membrane lifted off the posterior surface of the globe that floats and moves with eye movements.
- If large detachment, the membrane will be tethered to the optic nerve, But not if small detachment.
- Constant vision loss.
- Not too mobile; adheres closely to the wall.
- STAT referral to ophthalmologist.

Vitreous haemorrhage
- High gain.
- More obvious with eye movements.
- Hyperechoic particles (blood) swirling around in the vitreous body.

Posterior vitreous detachment
- Separation of vitreous body from posterior retina.
- Thin hyperechoic membrane lifted off posterior surface of globe that is not tethered to the optic nerve.
- Membrane moves with eye movements.
- Fluctuating vision blur.
- Very mobile, looks like swaying seaweed.

Central retinal artery occulusion
- The central retinal artery is a branch of the ophthalmic artery that travels within the optic nerve to supply blood to the retina.
- Occlusion of the central retinal artery is an ophthalmic emergency as the remaining posterior ciliary artery cannot sufficiently supply the retina s needs.
- Colour doppler.
- ↓ flow on central retinal artery.
- So might only see blue from central retinal vein, and no red from the central retinal artery.

Image from:
www.thepocusatlas.com

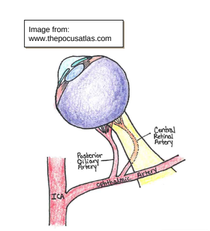

Normal

Abnormal

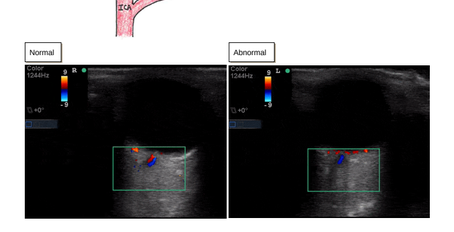

↑ ICP
- Any acute ↑ ICP causes distension of the occular nerve sheath.
- Transverse view.
- Rock probe laterally by 15o to see optic nerve.
- Go 3mm posterior from where the optic nerve attaches to retina.
- Then measure outermost lateral border of optic nerve sheath (the anechoic area).
- Normal diameter is <5mm.
- If > 5mm, indicates ↑ ICP.

Images from:
www.pocus101.com

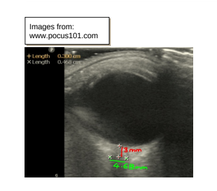

Papilloedema
- If chronic ↑ ICP causes not only the nerve sheath > 5mm, but also CSF accumulation in the optic nerve hence, the optic disc bulges into the retina > 0.6mm i.e. papilloedema.
- Causes:
- Brain mas.
- Hydrocephalus.
- Stroke.
- Idiopathic intracranial hypertension.
- Optic neuritis (if only one eye affected).

- Note: Pseudopapilledema causes same bulge but not nerve sheath dilation and no ↑ ICP.
- Occurs if a small crowded optic nerve head, tilted optic disc, or optic nerve head drusen.

VASCULATURE

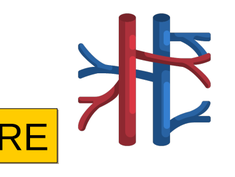

AORTA

- Position = Lying flat on couch. Ask them to bend legs to soften the abdo muscles.
- Probe = curvilinear.
- Location = Just below xiphoid process.
- Aorta is thick walled pulsatile circle, immediately above and left of the vertebral body, not compressible.
- IVC is less circular, right of the vertebral body, collapsible with respirations, compressible.
- Tip: If gas in the way, apply constant downward pressure and rock probe back and forth, if fails Lt lateral decubitus position.

Image from:
Ultrasound for the generalist. Sarb Clare, Chris Duncan. 2021

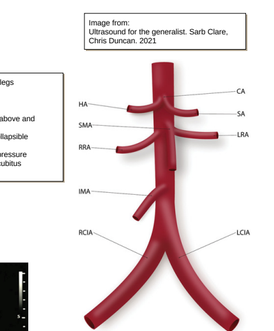

Image from:
www.pocus101.com

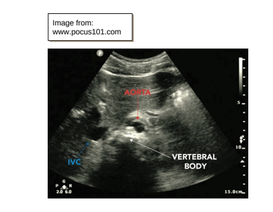

Aneurysm
- Measure widest diameter, outer wall to outer wall (white to white).
- Measure at three places.
- Proximal aorta just below sternum, keep aorta in view at all times and go measure at mid aorta just above renal arteries, and finally distal aorta just above umbilicus where it is most superficial.
- Go down further to see the bifurcation. Look for any aneurysms.
- Aneurysm = ≥ 3cm diameter for the abdominal aorta or a > 50% increase in the aortic diameter.
- Aneurysm = ≥ 1.5cm diameter for the iliac arteries.

GCA
- Position = Lying flat.
- Location = Tempal.
- Probe = Linear, power doppler.
- Sensitivity = 77%.
- Specificity = 96%.

- Look for wall thickening (halo sign).
- Non-compressible arteries (compression sign).
- Stenosis, variable lumen size.
- Vessel occlusion.

- Due to oedema of the artery wall and appears as hypoechoic thick wall.

Images from:
www.statpearls.com

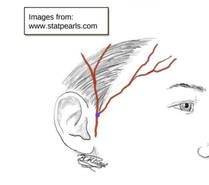

Image from:
Ultrasound for the generalist. Sarb Clare, Chris Duncan. 2021

Normal

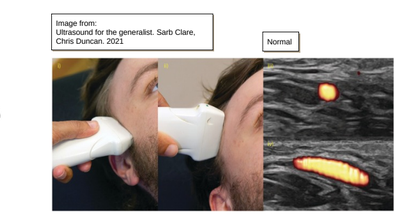

Abnormal; halo sign and irregular and variable lumen size with power doppler.

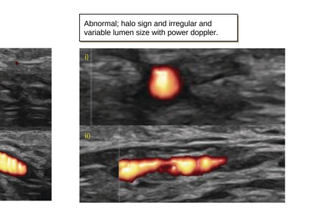

SKIN

Abscess
- Isolated fluid collection.
- Internal echoes.
- Septae.
- Swelling.
- Posterior acoustic enhancement.
- Soft tissue oedema.

Ultrasonography of Superficial Soft-Tissue Masses: Society of Radiologists in Ultrasound Consensus Conference Statement

RELIABLY BENIGN MASSES—Recommendation when typical: No further evaluation other than periodic self-monitoring

Pathology	Typical Findings	Atypical Findings	Recommendations When Atypical	Comments
Lipoma 	Isoechoic to hyperechoic Linear internal reflectors Oval Compressible No or minimal septal vascularity	Focal hyperechoic areas Abundant or focal vascularity Deep location Accelerated growth	Contrast-enhanced MRI Surgical consultation	
Fat Necrosis 	Hyperechoic Often poorly marginated Avascular History of trauma or injection	Hypoechoic Calcifications Liquified components Well marginated	Follow-up US Contrast-enhanced MRI Biopsy Surgical consultation	Fat necrosis has a variable appearance. Consider fat necrosis when lesions have a sonographic appearance that is not typical of any other condition.
Epidermal Inclusion Cyst 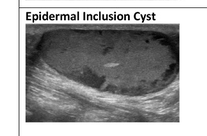	Minimally hyperechoic Internal linear echogenic and anechoic debris Broad contact with dermis Extension to dermis Round to oval Increased through transmission No internal blood flow "Pseudotestis"	Detectable internal blood flow Ill-defined margins Lobular margins Perilesional soft-tissue inflammation	Contrast-enhanced MRI Biopsy	Suspect rupture if margins are ill-defined and adjacent fat is focally hyperechoic or hyperemic.
Peripheral Nerve Sheath Tumor Schwannoma with eccentric entering and exiting nerve	Hypoechoic Round or ovoid hypoechoic mass Nerve continuity Increased posterior through-transmission Internal vascularity Severe pain with biopsy	No detectable nerve continuity Heterogeneous echogenicity Large Ill-defined margins Central necrosis Rapid growth	Contrast-enhanced MRI Surgical consultation	
Vascular Malformation 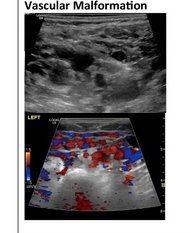	Heterogeneous hypoechoic and hyperechoic areas Variable vascularity Possible hyperechoic foci with shadowing	Associated mass Deep extension Increase in size Change in symptoms Possible hyperechoic foci with shadowing If associated mass, the US findings are not specific	Contrast-enhanced MRI	
Ganglion 	Hypoechoic or anechoic Multilocular or unilocular Non-compressible Possible septal vascularity No associated mass Characteristic location	Solid components Nonseptal vascularity Unusual location	Contrast-enhanced MRI	

PSEUDOMASSES—Recommendation when typical: Depends on the diagnosis. Follow-up US, aspiration, biopsy, or MRI may be required to help determine clinical management.

Pathology	Typical Findings	Atypical Findings	Recommendations when Atypical	Comments
Bursal Disease 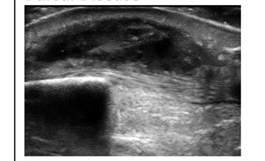 Prepatellar bursitis	Variable but commonly hypoechoic Well circumscribed Variable vascularity Location of an anatomic bursa or at site of extrinsic pressure (adventitious bursa)	Substantial solid components Vascularity in solid components	Contrast-enhanced MRI	Management is guided by clinical history given possible causes of trauma, inflammatory, and proliferative synovial processes; MRI may be considered to further characterize if proliferative; if concern for infection, then aspiration or synovial biopsy is recommended.
Abscess 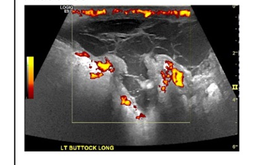	Variable heterogeneous echogenicity; commonly hypoechoic Increased through-transmission Mobile internal echoes with sonopalpation Adjacent edema or cellulitis No internal vascularity, possible peripheral hyperemia	Nonsupportive clinical history Internal vascularity Normal adjacent fat Deep location	Contrast-enhanced MRI biopsy or aspiration	Aspiration is usually required for cultures and cell count even when findings are typical, or to differentiate between an abscess and hematoma when the diagnosis is in doubt.
Foreign Body (wood) 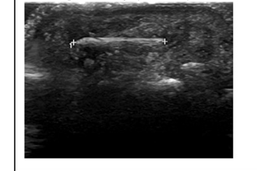	Echogenic foreign body (between cursors) Variable posterior acoustic shadowing Variable surrounding halo of fluid or hypoechoic inflammation Variable vascularity	Nonsupportive clinical history	Radiographic correlation CT or MRI	Surgical consultation
Hematoma 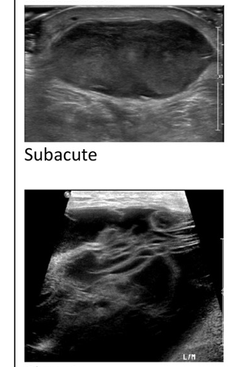 Subacute Chronic	Variable echogenicity ranging from hyperechoic (if acute) to anechoic (if chronic) Variable internal heterogeneity No associated mass Avascular History of trauma or anticoagulation	Nonsupportive clinical history Internal vascularity Deep location	US follow-up Contrast-enhanced MRI Biopsy or aspiration	Aspiration may be required to exclude superimposed infection, even when findings are typical.

LYMPHADENOPATHY—Recommendation when typical for a reactive node: Clinical follow-up

Pathology	Typical Findings	Atypical Findings	Recommendations when Atypical	Comments
Reactive/Hyperplastic 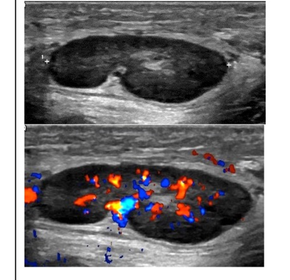	Mild to moderate enlargement Oval shape Echogenic hilum Uniform hypoechoic cortex Hilar vascularity (if present) Supportive clinical history	Marked enlargement Adenopathy at multiple sites Peripheral or disorganized vascularity Cystic areas Calcifications History of lymphoma or extranodal malignancy Lack of improvement on follow-up	Biopsy	Overlap in appearance of reactive and lymphomatous nodes makes distinction difficult. History, physical examination findings, and evolution on follow-up guides decision to recommend biopsy.
Lymphoma/Leukemia 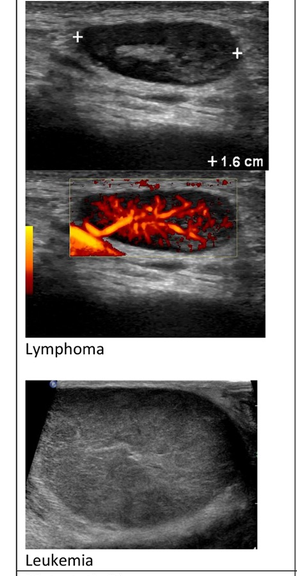 Lymphoma Leukemia	Mild to marked enlargement Oval or round shape With or without echogenic hilum Uniform hypoechoic cortex Hilar vascularity Supportive additional imaging and clinical history	Hyperechoic or heterogeneous cortex One site of adenopathy Peripheral or disorganized vascularity Cystic areas Calcifications Nonsupportive clinical history	Biopsy	Overlap in appearance of reactive and lymphomatous nodes makes distinction difficult. History, physical examination findings, and evolution on follow-up guides decision to recommend biopsy.
Metastatic Disease 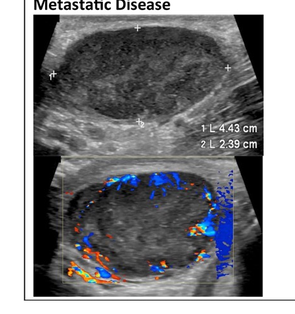	Mild to marked enlargement Oval or round shape With or without echogenic hilum Eccentric cortical thickening Heterogeneous cortex Calcification Cystic areas Variable vascularity Supportive additional imaging and clinical history	Nonsupportive clinical history Contradictory results on other imaging	Clinical and US follow-up	Recommendation for nodes with typical findings of metastatic disease depends on the clinical scenario. Options primarily include biopsy or further imaging and staging examinations.