Seborrhoeic keratosis (SK) / Basal cell papilloma

- These are originating from basal cells, but rather than making a BCC, they make SK instead i.e. benign.
- Try to avoid seborrhoeic wart, as it is not a wart virus, it just looks a little warty sometimes.

- Non-polorised light will pick up the milia and comedo.
- Use with gel.

? Do you also see comma vessels

SK
cerebriform, hairpin vessels, comedo openings, milia cyts, moth eaten edge, sharp edge,
they volve so initially fat fingers then cerbriform patterns.

Difficult in few cases:

- If inflammed get prominent blood vessels, still hairpin and milky halo around the vessels
have is fine for keratinised and well differentated scc.
they often get referred on 2ww inpapropriately. better to just bring them back in a few weeks to see if settles.

- Immune reaction, the body says 'i want to get rid of these
so get granular pigmentation like pepper#ll ground all over it.
if see grey = think. do not just cut out. if all explainable leave it alone.
99% of grey will be nice if epidermal lesion.

- trauma. look for whats left behind.
can give dermovate for 2 weeks and review to ensure settled.
if still there can always biopsy it.

- Appear from 20's onwards.
- Slow growth.
- Most commonly on sun protected areas.
- Stuck on appearance.
- Sharply demarcated i.e. lesion version normal skin is a sharp border.
- Moth-eaten borders.
- Deep crevices and cracks.
- Amorphous waxy stroma (looks like candle wax that has solidified i.e. no structure to it at all).
- No pigmentation.
- Skin background colour can be black, blue, grey, brown or yellow.
- Symmetically distributed tan to brown perifollicular pigmentation.
- Milia-like cyst (white/yellow shiny dots and globules). Bundles of keratin which are in the epidermis and have not yet reached the surface.
- Comedo-like openings (black/brown/yellow, demarcated roundish structures). When the keratin bundles rupture and reach the surface and become oxidized.
- These structures need to be multiple to be suggestive of seborrhoeic keratosis.
- Cerebriform/brain like structures. Sometimes located at periphery (come straight at you in centre so can't see hairpin shape there).
- Jelly sign. Brown semicircular U-shaped structures that have a smudged appearance and are all aligned in the same direction e.g. appearance of jelly as it gets spread on a piece of bread.
- Wobble sign negative. Differentiates between an epidermal keratinocytic lesion and a lesion with a dermal component such as a compound or dermal melanocytic neoplasm. Wobble sign is performed by moving the dermatoscope across the skin surface (parallel to the surface). If the lesion slides across the skin surface, following the movement of the dermatoscope, it favors a diagnosis of SK. If it rolls back and forward (wobbles) then more likely an intradermal or compound melanocytic neoplasm.
- Fingerprint-like structures.
- Frogspore/pigmentated circles on non-facial skin.
- If your not sure if it's a seb k, you can put some local anaesthetic in and loope curnette it off. And if it comes away in little bits, then it ain't a melanoma. You cannot pick off a melanoma.
- There are various 'versions' of SK (See below).

Disclaimer:
Read the disclaimer at medimaps.co.uk/disclaimer

References:
1. An Introduction to Dermoscopy, Cardiff university
2. Dr George Moncrieff webinar Nov 2020
3. Pocket Guide to Dermoscopy
4. DrWeda.com

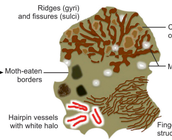

Pigmented circles

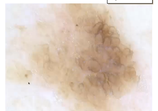

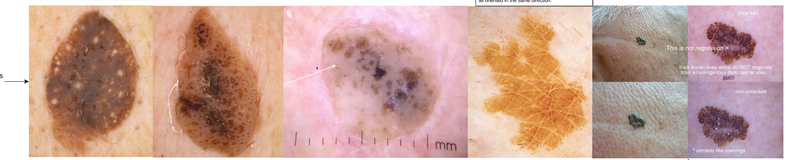

Jelly sign, brown semicircular U-shaped structures all oriented in the same direction.

- "Whilst the streaks of a melanocytic lesion always arise from a heavily pigmented centre..."
- If you look very closely at the macro you can see tiny dots in the surface.
- And look closely at the bottom right picture and you can make out the comedo like openings, near the centre.
- It's not regression in the centre, just a slightly annular shaped seborrhoeic keratosis.
- These are just lots of fat brown lines - there is no heavily pigmented central area.

Cerebriform/Brain like pattern:
- Sometimes the surface has a brain like surface.
- The sulci are extended comedo-like openings.

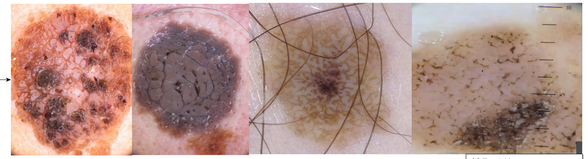

- Jelly like material
- The 'cracks' are extended comedo like openings.
- Large area of keratin at 5 o'clock.

Reticulated:
- This is differentiated from naevi and melanoma by the sharp demarcation at the border.

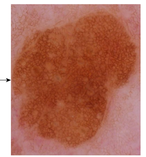

Hyperkeratotic:
- The white/yellow areas make it difficult to assess the underlying structures.

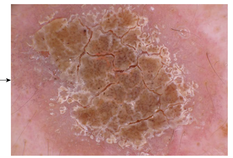

Melanoacanthoma:
- Intensely pigmented.
- But you should still be able to make out the milia and comedo.
- Notice the sharply demarcated border (jelly sign).

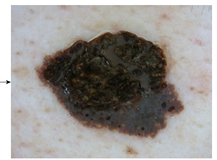

Irritated SK:
- Variable combination of pigmented and vascular structures giving the lesion an atypical morphology.
- These features are shared amongst SK, keratoacanthomas or scc.

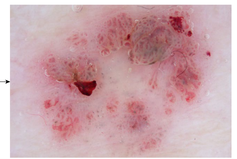

Lichen planus-like keratosis (LPLK) (Lichenoid keratosis)

- Immunologic (lymphocytes and melanophages) or inflammatory response to a pre-existing lesion i.e. Seb K, solar lentigo or AK. Unknown what triggers this process.
- Macrophages come rushing in and take away the melanin and form melanophages.
- The inflammation is confined to the edge of the lesion.
- Can completely clear the lesion and restore normal skin.

- RULE:
- LPLK cannot be differentiated confidently from regressive melanoma so must be excised.
- Although GPwSI says can leave and it completely resolves.

- Dermoscopic structures of the original lesion can be seen in the remainder of the lesion i.e. portions of Seb K, solar lentigo or AK structures.
- Macule or plaque, tan to brown or pink in colour.
- Blue-grey pepper like granules (or iron fillings like) predominate.
- These features are shared with a regressing melanoma, hence the RULE.
- Granules in LPLK tend to be larger and coarser than those present in melanomas undergoing regression.

- Localized granular pattern with grey-brown granules (square).
- The LPLK in this case represents an involuting Seb K.
- Structures of the original seborrheic keratosis (comedo-like opening and milia-like cysts) can be visualized in the upper portion of the lesion.

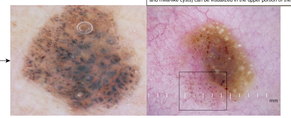

Diffuse granular pattern
- Granules are brown, gray, blue-gray or white-gray in color, and tend to present in a diffuse manner, scattered throughout the lesion.

Localized granular pattern
- Granules are greybrown, focally distributed.

Agranular pattern
- Some do not have a granular pattern but instead appear as pink to tan macular lesions with shiny white lines (seen only with polorising light).
- May even have a few vessels.
- Lesions with this morphology are difficult to differentiate from superficial BCC and amelanotic melanoma.

Solar lentigo

- Some solar lentiggo are precursors to SK and others may be non-obligated precursors to Lentigo meligna.

Ink spot lentigo

- A variant of a solar lentigo.

- Prominent dark brown to black uniform network that appears sharply infiscus and superficial.

- Similar to SK with 5 features below but are flat macules rather than being raised or stuck on appearance.
- Sharply demarcated.
- Moth-eaten borders.
- Fingerprint-like structures.
- Symmetrically distributed tan to brown perifollicular pigmentation.
- Jelly sign. Brown semicircular U-shaped structures that have a smudged appearance and are all aligned in the same direction. e.g. appearance of jelly as it gets spread on a piece of bread.
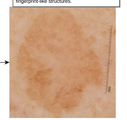
- Sharp demarcation, moiheaten borders, and fingerprint-like structures.