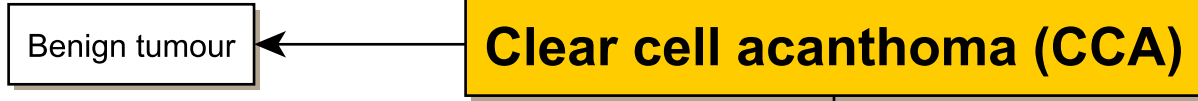


CLEAR CELL ACANTHOMA (CCA)

Disclaimer:
Read the disclaimer at medimaps.co.uk/disclaimer

References:
1. An Introduction to Dermoscopy, Cardiff university
2. Pocket Guide to Dermoscopy



- Slow-growing.
- Erythematous papule with a collaret of scale.
- Dotted or glomerular vessels arranged in a serpiginous or “string of pearls” and has a 100% specificity for CCA.

